

Clinical Research

Short-term outcome of ceramic-on-ceramic total hip replacement in young adult patients

Ismail H. Dologo, William Chandra

Department of Orthopaedic and Traumatology, Faculty of Medicine, Universitas Indonesia, Cipto Mangunkusumo Hospital, Jakarta, Indonesia

ABSTRAK

Latar belakang: Ceramic-on-ceramic (CoC) total hip replacement (THR) telah dikembangkan untuk mengurangi debris dan reaksi osteolisis pascaoperasi. Permasalahan utama dari penggunaan CoC adalah kerapuhannya. Studi ini bertujuan untuk mengevaluasi hasil jangka pendek terapi THR dengan menggunakan CoC pada pasien dewasa muda.

Metode: 11 pasien dengan total 13 prosedur operasi THR diikuti selama enam bulan pascaoperasi. Seluruh pasien dievaluasi dengan menggunakan Harris hip score (HHS), visual analog scale (VAS), keluhan pasien, and short form-36 (SF-36), acetabular dan femoral component angles. Data dianalisis dengan uji Wilcoxon signed rank, uji-t berpasangan, dan uji Spearman.

Hasil: Rerata pasien berumur 33,6 tahun dan didominasi perempuan (55%). Systemic lupus erythematosus (SLE) adalah penyakit utama yang mendasari dilakukannya operasi THR. Skor VAS sesudah operasi menurun dibandingkan sebelum operasi (5 ke 1). Rerata HHS dan SF-36 meningkat secara bermakna sebelum dan sesudah operasi; (25 ke 92) dan (21 ke 54). Insidens bunyi squeaking 2 pasien. Tidak terdapat hubungan bermakna antara acetabular dan femoral component dengan insidens bunyi squeaking.

Kesimpulan: CoC THR telah menunjukkan hasil yang baik untuk pasien dewasa muda. Jika dikombinasi sesuai indikasi yang tepat, dapat diyakini bahwa CoC THR menghasilkan luaran yang baik dan waktu bertahan yang menjanjikan.

Keywords: ceramic-on-ceramic, short term outcome, total hip replacement, young adult

pISSN: 0853-1773 • eISSN: 2252-8083 • <http://dx.doi.org/10.13181/mji.v24i3.1184> • Med J Indones. 2015;24:163-7

• Received 11 Jan 2015 • Accepted 27 May 2015

ABSTRACT

Background: Ceramic-on-ceramic (CoC) total hip replacement (THR) was developed to minimize debris and osteolytic reaction. The major concern is its brittleness. The aim of this study was to evaluate the short-term outcome of CoC THR in young adult patients.

Methods: 11 patients, 13 THR procedures, were followed up until six months after surgery in Cipto Mangunkusumo Hospital. Evaluation included Harris hip score (HHS), visual analog scale (VAS), patients' complaint, short form-36 (SF-36), and acetabular and femoral component angles. Data were analyzed using Wilcoxon signed rank test, paired t-test, and Spearman test.

Results: The average age of the patients was 33.6 years old and 55% of them were female. Systemic lupus erythematosus was the main causative disease for THR. The VAS average decreased before surgery and after six months of surgery (5 to 1). Pre- and post-operative HHS and SF-36 increased significantly by (25 to 92) and (21 to 54) respectively. Squeaking sound was reported by two patients. No correlation was found between acetabular and femoral component and squeaking incidence.

Conclusion: CoC THR showed excellent short term outcome for young adult patients. With proper indications, CoC THR ensures excellent clinical outcomes and promising survivorship.

Correspondence author: **Ismail H. Dologo**, ismailorthofkui@yahoo.co.id

Total hip replacement (THR) is among the most successful orthopaedic surgical procedures and has regained popularity during the last decade. The rapidly developing operating techniques and excellent quality of the implants minimize the complexity of procedure and provides rapid recovery of patients.¹ All of these have provided this procedure as a treatment of choice, even in young adult patients. In the United States, THR is carried out closer to a million in a year (population 308 millions). In Australia, over 30,000 metal-on-metal (MoM) hip replacements were carried out between 1999 and 2010 (population 21.5 millions).²

Metal-on-polyethylene (MoP) is the most commonly implanted articulation nowadays, while MoM and ceramic-on-ceramic (CoC) are less frequently used. MoP couplings is proven to be associated with debris particles that can induce preprosthetic inflammation and osteolysis, all of these reactions lead to implant failure. Then, MoM couplings had also proven to elevate serum level of metal ion in the body. This may lead to renal toxicity or chromosomal aberrations. There has been no reported increase in the risk of cancer after THR with conventional MoP or first generation MoM implants.¹⁻³

Nowadays, CoC articulations are increasingly applied in THR with satisfactory long-term outcome. Its special features include the high resistant to scratch, high wettability, inert, and smooth surface. All of these minimize the risk of wear and periprosthetic osteolysis. We can predict more applications of CoC articulation in THR.^{3,4}

Yet, the major concern is its brittleness. Ceramic materials able to minimally withstand the plastic deformation. The loads will induce micro-fracture that potentially leads to implant failure.⁵⁻⁸ In addition, there is a consideration of transient squeaking sound. This problem was elusive and likely to be multifactorial in nature. Hannouche, et al³ found that there was no association between squeaking sound and the implant component. Synder, et al¹ stated that 12-years survival for the whole prosthesis with CoC articulation is 86.36%. Yeung, et al⁴ observed that the overall survival rate of the implants was 98% at 10 years with average HHS of 94 points.^{3,5,9,10}

The aim of this study was to evaluate the short-term outcome, incidence of squeaking complication, and its relation to implant component in young adults underwent THR with CoC couplings.

METHODS

This descriptive-analytical study included young adult patients who had undergone THR with CoC couplings at Department of Orthopaedic and Traumatology Cipto Mangunkusumo Hospital, Jakarta, Indonesia in 2013. We investigated 13 THR with CoC performed in 11 patients with a minimum of six months follow up. All of THR were performed by a single experienced orthopaedic surgeon. The implants were supplied by one health instrument providers (Deputy Johnson and Johnson). The entire data were taken from the medical records and confidentiality of subject identity was guaranteed.

We assessed the clinical signs and symptoms using SF-36, VAS, HHS, and radiologic evaluations in preoperative as well as six months after surgery. HHS score of 90 points or more was categorized as an excellent outcome; 80-89 points, a good outcome; 70-79 points, a fair outcome; less than 70 points, a poor outcome. The patients were interviewed using SF-36 preoperatively and at six months follow up. Average score > 50 was defined as the the lowest point of being average in each of physical health category and mental category.

VAS scoring were performed by asking the patients to point out on the pain scale, to which was most suitable to describe the level of pain. The acetabular component was assessed by measuring the lateral inclination angle and anteversion angle from post-operative radiographs. Femoral anteversion angle was obtained from the post-operation hip axial radiographs. In addition, the acetabular and femoral components would be compared to incidence of squeaking as a complication of THR. All the data were collected and analyzed using Wilcoxon signed rank test, paired t-test, and Spearman test using SPSS v. 22.0.

RESULTS

Thirteen hips in 11 patients were available for six months follow-up of clinical examination at

Orthopaedic and Traumatology Department, Universitas Indonesia, Cipto Mangunkusumo Hospital, Jakarta, Indonesia. The average age of patients underwent CoC THR was 34 ± 11.7 years old. Six out of 11 of the patients were female. Radiological examinations were taken before and after surgery.

Five patients (45%) underwent CoC THR because of systemic lupus erythematosus (SLE) as underlying disease. One patient (9%) had ankylosing spondylitis, two patients (18%) had osteoarthritis, one patient (9%) had rheumatoid arthritis, and two patients (18%) had tuberculosis of the bone.

Table 1. The HHS, SF-36 physical status, SF-36 mental status, and VAS in patients undergoing CoC THR before and six months after surgery

	Pre-surgery	6 months post-surgery	p
Harris hip scale (HHS)	25 (2-49)	86 (43-97)	0.003*
SF-36 physical status	23 (16-43)	53.81 (50-59)	0.003*
SF-36 mentalstatus	39(39± 5.3)	56.63 (57 ± 2)	0.000 #
Visual analog scale (VAS)	5 (4-6)	1 (0-2)	0.003*

*Wilcoxon Signed Rank Test; #paired t- test

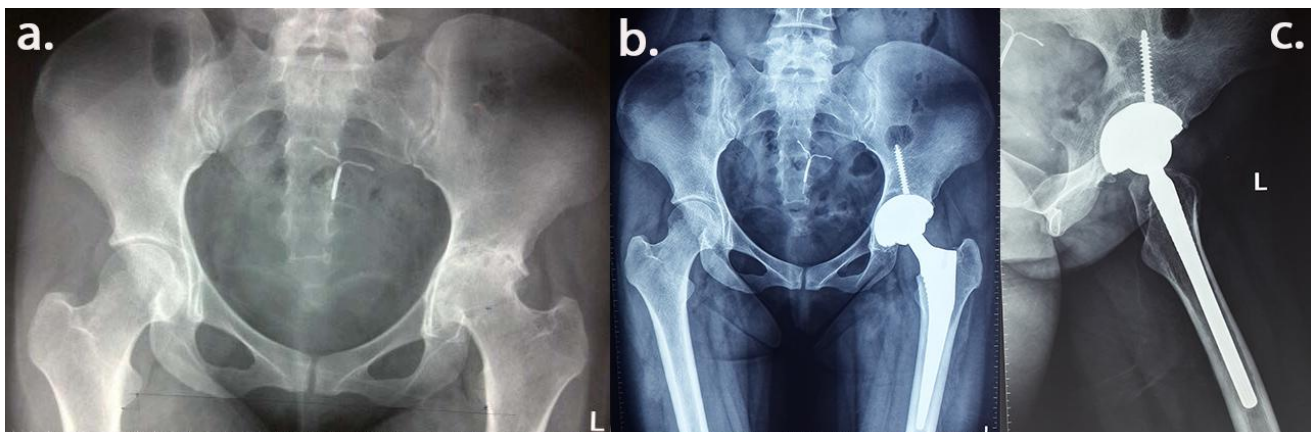


Figure 1. CoC THR in young adult patient with rheumatoid arthritis. A) pelvic radiograph before surgery; B and C) post- CoC THR radiography

Table 2. Lateral inclination, acetabular cup and femoral anteversion in patients undergoing CoC THR

		Spearman correlation with squeaking incidence (R)
Acetabular lateral inclination	$37^\circ \pm 6.74^\circ$	0.341
Acetabular anteversion	$15^\circ (10^\circ - 40^\circ)$	0.442
Femoral anteversion	$19.5^\circ (10^\circ - 27^\circ)$	0.116

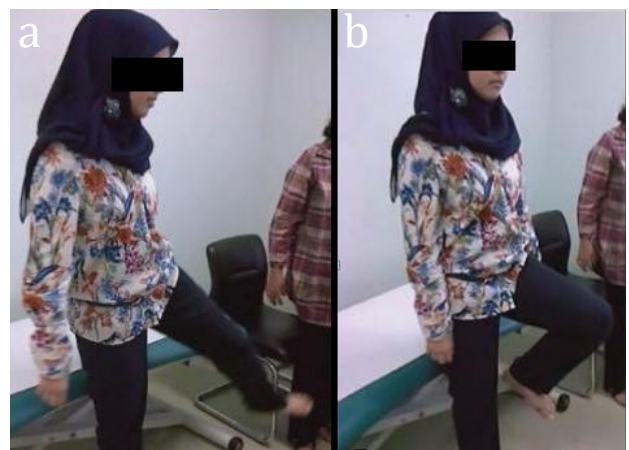


Figure 2. (A,B) Clinical examination of a female patient after CoC total hip replacement. The patient had no difficulty to perform hip extension and abduction

DISCUSSION

In our study, we found that CoC THR was performed in patients with the average age of 34 year old because of avascular necrosis (AVN) with SLE and tuberculosis. This finding was similar to studies conducted by Synder, et al¹ and So, et al⁶. Synder, et al¹ stated that 70% THR surgery was performed in under 50 year old patients. It was related to the high survival rates free of revision of 90.8 - 97.4% at 10 years.

In Cipto Mangunkusumo Hospital, there were more females who underwent THR. It was similar to the study of Synder, et al¹ (101 female and 87 male) and So, et al⁶ (78 female and 14 male). Our patients mostly had AVN of hip with SLE as the underlying cause, while So, et al⁶ reported secondary osteoarthritis due to developmental dysplasia of the hip as the most common underlying disease, while osteoarthritis and rheumatoid arthritis of the hip were found as the second most underlying disease at his study. Synder, et al¹ also found that the most underlying disease was dysplastic hip in childhood. We got different results from them. It seems that the small sample size in our study and low screening rate for congenital dislocation of the hip as well as high usage of long term steroid for SLE treatment, were the cause of these different findings. Ortiguera, et al¹¹ found that the dislocation rate is significantly higher in AVN than in OA patients, due to the less stiffness in AVN patients resulting in larger range of motion and thus, prone to dislocation. Berry, et al¹² studied that AVN cases had more than two fold greater cumulative risk for dislocation than osteoarthritis cases. Millar, et al¹³ stated that eventhough non-cemented CoC THR was applied, osteoarthritis patients had better clinical outcome than osteonecrosis patients.

The VAS decreased significantly while the inversed was observed for the HHS. It is similar to Yeung, et al⁴ which showed that the average HHS was 94 points in 301 THR alumina-on-alumina ceramic bearings. We also found 81.8% patients had excellent or good results as also reported by Yeung, et al⁴ that 95% of the patients have excellent or good results. Synder, et al¹ found that 83.1% patients had excellent and good results by having CoC THR. Solarino, et al⁷ found that HHS was 90.7 ± 5.8 points and

96.7% had excellent and good results. The SF-36, both physical and mental status were found significantly increased at six months follow-up. HHS was assessed objectively by the physician by interviewing and providing some motion to the patient's hip while SF-36 was assessed subjectively by the patients by answering the questions. These two tools provided both clinical assessment from the physician and patient side. This significant increase was thought due to the low friction, high wear resistance and low rate of osteolysis.

Periprosthetic osteolysis was related to systemic reaction against the prosthesis, releasing micro-components which induced systemic inflammation. Metalloproteinases and osteoclast were attracted to enhance the osteolytic process.¹⁻³ Affatato, et al¹⁴ stated that the rate of polyethylene wear is 0.01-0.3 mm/year, hence the wear for ceramic is just 0.13-78 μm . Less micro-components also induced less osteolytic reaction in periprosthetic implant and finally extend the life span of prosthesis.

Squeaking was reported by two patients (15%). McDonnell, et al⁵ found that 13% of patients had reproducible squeaking after THR. Squeaking had multifactorial reason without any conclusion. Taylor, et al⁹ showed that squeaking was occurred when femoral head subluxates across the edge. Walter, et al¹⁵ suggested that squeaking could be the resonance of any metal component during edge loading. We found that the incidence of squeaking was not associated with the acetabular cup anterversion and lateral inclination neither with the femoral anteversion. Similar results were also reported by Restrepo, et al¹⁶ and Hannouche, et al³ that the implant position was equal between the squeaking and the non-squeaking. Despite the surprisingly high incidence of squeaking, all patients remained satisfied with their hip replacement.

In conclusion, six months follow-up of total hip replacement using ceramic on ceramic couplings are fairly encouraging. The HHS and SF-36 increased significantly while VAS markedly decreased. Squeaking was found in two patients and was not associated with acetabular lateral inclination and anterversion nor with femoral anteversion. Combined with proper indications, CoC THR ensures good clinical outcomes.

Acknowledgment

The authors would like to thank to the Department of Orthopaedic and Traumatology in Cipto Mangunkusumo Hospital, Faculty of Medicine, Universitas Indonesia and all of has contributed to this study.

Conflict of interest

The authors affirm no conflict of interest in this study.

REFERENCES

1. Synder M, Drobniowski M, Sibiński M. Long-term results of cementless hip arthroplasty with ceramic-on-ceramic articulation. *Int Orthop*. 2012;36(11):2225-9.
2. Sugano N, Takao M, Sakai T, Nishii T, Miki H, Ohzono K. Eleven-to 14-year follow-up results of cementless total hip arthroplasty using a third-generation alumina ceramic-on-ceramic bearing. *J Arthroplasty*. 2011;27(5):736-41.
3. Hannouche D, Zaoui A, Zadegan F, Sedel L, Nizard R. Thirty years of experience with alumina-on-alumina bearing in total hip arthroplasty. *Int Orthop*. 2011 Feb; 35(2):207-13.
4. Yeung E, Bott PT, Chana R, Jackson MP, Holloway I, Walter WL, et al. Mid-term results of third-generation alumina-on-alumina ceramic bearings in cementless total hip arthroplasty: a ten-year minimum follow up. *J Bone Joint Surg Am*. 2012;94(2):138-44.
5. McDonnell SM, Boyce G, Baré J, Young D, Shimmin AJ. The incidence of noise generation arising from the large-diameter Delta Motion ceramic total hip bearing. *Bone Joint J*. 2013;95-B(2):160-5.
6. So K, Kanatani TK, Kuroda Y, Nakamura T, Matsuda S, Akiyama H. Good short-term outcome of primary total hip arthroplasty with cementless bioactive glass ceramic bottom-coated implants: 109 hips followed for 3-9 years. *Acta Orthop*. 2012;83(6):599-603.
7. Solarino G, Piazzolla A, Notarnicola A, Moretti L, Tafuri L, De Giorgi S, et al. Long-term results of 32-mm alumina-on-alumina THA for avascular necrosis of the femoral head. *J Orthop Traumatol*. 2012;13(1):21-7.
8. D'Antonio JA, Capello WN, Naughton M. Ceramic bearings for total hip arthroplasty have high survivorship at 10 years. *Clin Orthop Relat Res*. 2012;470(2):373-81.
9. Taylor S, Manley MT, Sutton K. The role of stripe wear in causing acoustic emissions from alumina ceramic-on-ceramic bearings. *J Arthroplasty*. 2007;22(7Suppl3):47-51.
10. Chevillotte C, Pibarot V, Carret JP, Bejui-Hugues J, Guyen O. Hip squeaking: a 10-year follow-up study. *J Arthroplasty*. 2012;27(6):1008-13.
11. Ortiguera CJ, Pulliam IT, Cabanela ME. Total hip arthroplasty for osteonecrosis: matched-pair analysis of 188 hips with long-term follow-up. *J Arthroplasty*. 1999;14(1):21-8.
12. Berry DJ, Harmsen WS, Cabanela ME, Morrey BF. Twenty-five-year survivorship of two thousand consecutive primary charnley total hip replacements: factors affecting survivorship of acetabular and femoral components. *J Bone Joint Surg Am*. 2002;84-A(2):171-7
13. Millar NL, Halai M, McKenna R, McGraw IW, Millar LL, Hadidi M. Uncemented ceramic-on-ceramic THA in adults with osteonecrosis of the femoral head. *Orthopedics*. 2010;33(11):795.
14. Affatato S, Traina F, Toni A. Microseparation and stripe wear in alumina-on-alumina hip implants. *Int J Artif Organs*. 2011;34(6):506-12.
15. Walter WL, Insley GM, Walter WK, Tuke MA. Edge loading in third generation alumina ceramic-on-ceramic bearings: stripe wear. *J Arthroplasty*. 2004;19(4):402-13.
16. Restrepo C, Matar WY, Parvizi J, Rothman RH, Hozack WJ. Natural history of squeaking after total hip arthroplasty. *Clin Orthop Relat Res*. 2010;468(9):2340-5.